

Surgical outcomes of 23-gauge pars plana vitrectomy for retinal detachment patients in Tripoli

▪ Dr-Khalifa Alswidi*

▪ Rania massoud Alrujbani**

Abstract

Aim:

To evaluate the outcomes and complications of 23-gauge (G) pars plana vitrectomy (PPV) for repair of retinal detachment (RD).

Method:

Retrospective review of consecutive, single-surgeon 23-G PPV cases between January 2017 and December 2017. 117 eyes from 117 patients were operated on for RD; all eyes were tamponaded with , silicone oil, Air.

Mean age at surgery was 48.69 years (range 8–75 years), and mean length of follow-up was 5 weeks (range 2 weeks – 32 weeks).

Primary outcomes included best-corrected visual acuity (BCVA), intraocular pressure (IOP), anatomic success, redetachment, and endophthalmitis.

Result:

We included 117 consecutive patients (117 eyes). Males and females are equal . The average age was 48,69 years (range 8-75), The primary success rate with a single procedure was 98%. However, redetachment occurred in two eyes only (1.7%). Visual acuity was improve in 89.74% of the eyes. Mean IOP increased from 11.16 to 12.58 mm Hg after surgery.

Elevated postoperative IOP (≥ 22 mm Hg) occurred in 10 eyes, and no low IOP .

There were no cases of endophthalmitis . The average follow-up period for all patients was 2 weeks (range 2-32 weeks)

Conclusion:

Twenty-three-G PPV repair was safe and effective in the repair of RD,

* Viteoretinal consultant surgeon ophthalmology lectures in tripoli university

** ophthalmologist in tripoli eye hospital

including eyes with a combined rhegmatogenous detachment or PVR.

air, silicone oil, tamponading agents all proved to be efficacious in this surgical population.

Introduction :

A retinal detachment is a separation of the sensory retina from the retinal pigment epithelium, with an accumulation of fluid in the potential space between them. Retinal detachments can be rhegmatogenous (caused by a break in the retina) or non-rhegmatogenous (caused by leakage from beneath the retina or by traction (pulling) on the retina).(12)

In about 5–10% of cases of retinal detachment, anatomical and visual prognoses are complicated by proliferative vitreoretinopathy(PVR).(15)

Rhegmatogenous retinal detachment (RRD) is a separation of neurosensory retina from underneath layer of retinal pigment epithelium (RPE) in presence of at least one retinal break. In 1904, retinal detachment (RD) was declared as an untreatable disorder at the International Congress in Paris.(28)

Gonin, who found out that retinal breaks are the primary cause of RRD, described in 1920 for the first time successful treatment for RRD by localizing the tears, draining subretinal fluid using cautery and bed rest,His technique had 50% success rate.(13)

Scleral buckle technique was introduced in 1951 by Charles L. Schepens with a success rate close to 90%. [3] In 1970, pars plana vitrectomy (PPV) was introduced by Robert Machemer as an alternative treatment for RRD.(28)

Most recently in 1986, Hilton and Grizzard introduced pneumatic retinopexy as a treatment for RRD as an outpatient procedure.[13]

Diabetic retinopathy (DR) is a common microvascular complication of diabetes mellitus (DM) and remains a leading cause of vision loss in many developed countries(18), Proliferative diabetic retinopathy (PDR) is an advanced stage of diabetic microangiopathy that may cause loss of vision from intraocular hemorrhage, traction retinal detachment, and neovascular glaucoma.(36)

Tractional retinal detachment (TRD) is a major cause of vision loss in

patients with proliferative diabetic retinopathy (PDR).(12,15)

The studies such as the Early Treatment of Diabetic Retinopathy Study (ETDRS) and The Diabetic Retinopathy Study (DRS) have convincingly shown the benefits of panretinal laser photocoagulation (PRP) to reduce the risk of development of proliferative diabetic retinopathy (PDR) and tractional retinal *detachment* (TRD).(21,33)

Although panretinal photocoagulation (PRP) reduces the 5-year risk of blindness by 90%,²¹ there is no doubt that DR with vitreous hemorrhage or tractional retinal detachments needs surgical approach such as vitrectomy, but intraoperative and postoperative bleeding may increase surgical difficulty and compromise surgical effect as well. (16,33)

Technological advancements in vitreoretinal surgery have made it possible to surgically treat certain diseases which had been considered hard for a long time. Invented by Machemer in the early 1970s, the “pars plana vitrectomy” technique has led to an increasingly more advanced and promising treatment, which calls for limited intervention, Introduced for the first time by Claus Eckardt, the 23-gauge (23G) transconjunctival vitrectomy technique is commonly accepted by vitreoretinal surgeons in daily practice.(17)

23-G vitrectomy was originally reported by Hilton in 1995 as a two-sclerotomy technique and it was subsequently developed by Eckardt in 2005 as a three-way primary pars plana vitrectomy technique (18,36)

More recently, improved visual outcomes and superior anatomic benefits were reported with 23-G vitrectomy in different vitreoretinal disorders, such as RD, macular holes (MH), proliferative diabetic retinopathy, epiretinal membranes (ERM), and vitreous hemorrhage (21).

Previous published studies demonstrated the strong advantages of 23-G vitrectomy over 20-G vitrectomy, but several other studies noted complications, such as increased incidences of postoperative hypotony, endophthalmitis, and macular hole MH, using the 23-G system (33,44,43).

In view of the ambiguous data from different studies regarding the comparative clinical efficacies of 23-G vitrectomy and 20-G vitrectomy in the repair of RD.

23-G vitrectomy is a safe and reproducible technique for the management of RD. Similarly, there is previous evidence showing 23-G vitrectomy has the advantage of accelerated wound recovery in the study of Yanyali et al., the sclerotomy size in 23-G vitrectomy is just 0.6 mm compared to 0.89 mm in 20-G vitrectomy; thus, a minimally invasive wound with a protective drivepipe that can prevent the wound from damage in 23-G vitrectomy may explain the shorter wound closure time in 23-G vitrectomy. (6 ,15)

the 23-G vitrectomy instruments are characterized by greater stiffness and edge stability, reducing the risk of retinal impairment in vascular membrane fiber tissue segmentation, which may be another reason for the shorter wound closure time in 23-G vitrectomy (1). Consistent with our results.

One major difficulty with this procedure is the transparency of the vitreous. Intra-operative triamcinolone acetonide (TA) has been used to address this problem, as it can be injected into the vitreous to visualize the posterior hyaloid or the internal limiting membrane (ILM) (37).

Several previous reports have demonstrated the usefulness of TA as an adjunct to pars plana vitrectomy (PPV) (26).

the intravitreal application of brilliant blue G (BBG) has gained popularity to visualize the internal limiting membrane (ILM).

In contrast to other vital dyes such as indocyanine green (ICG), BBG was shown to have a good safety profile providing satisfactory anatomical and functional postoperative results ²³.

However, the presence of epiretinal membrane (ERM) formation may impair sufficient staining and complete removal of the ILM, which may result ERM recurrences due to residual ILM fragments including indefinite extent of cells and collagen remnants at the vitreal side of the ILM ³⁰.

In a previous study Shimada et al.⁹ found BBG has high affinity to ILM and low affinity to ERM.

reported that 23-G vitrectomy reduced operating time, improved patient comfort, accelerated wound healing and visual recovery, and reduced postoperative astigmatism (22,2).

The use of preoperative intravitreal injection of bevacizumab (IVB)

(Avastin, Genentech Inc., South San Francisco, CA, USA) may potentially further improve diabetic vitrectomy outcome.

This vascular endothelial growth factor inhibitor has been reported to decrease intraoperative hemorrhage and facilitate fibrovascular membrane dissection,⁴⁴ and reduce postoperative vitreous hemorrhage (VH) rates.⁶

By blocking the effect of vascular endothelial growth factor (VEGF), intravitreal anti-VEGF drugs could decrease vascular permeability and proliferation, thus improving macular edema and reducing the risk of intraocular bleeding in patients with PDR.¹

The most commonly used anti-VEGF drug is Bevacizumab. However, there were reports about it causing tractional retinal detachment (TRD) in cases with pre-existing preretinal fibrosis.²²

On the other hand, being licensed as an intravitreal agent for the treatment of wet age-related macular degeneration (AMD), Ranibizumab is an engineered, humanized, recombinant antibody fragment active against all VEGF-A isoforms and has a shorter half-life than other anti-VEGF agents.²

patients who did not have Lucentis injection, intraoperative bleeding was more prone to occur and hard to stop, thus extending surgical duration.⁽³⁷⁾

Aflibercept (Eylea; Regeneron, Tarrytown, New York, USA and Bayer Healthcare, Leverkusen, Germany) is a fusion protein consisting of the Fc portion of human immunoglobulin IgG1 and the extracellular domains of vascular endothelial growth factor receptors (VEGFR-2 and VEGFR-1), which binds to circulating vascular endothelial growth factor (VEGF), thus acting as a decoy receptor. Laboratory studies and clinical trials suggest that aflibercept's high binding affinity for VEGF may impart greater durability of activity and similar efficacy compared with ranibizumab ⁽²⁹⁾ or bevacizumab.

Aflibercept is approved by the US Food and Drug Administration (FDA) for the treatment of wet age-related macular degeneration (AMD), macular oedema from retinal vein occlusion or diabetes.⁽²⁹⁾

Ziv-aflibercept (Zaltrap; Regeneron, New York, USA) is structurally isomeric with aflibercept, and acts on all VEGF subtypes, as well as placental growth factor. It is currently FDA-approved for metastatic colorectal

cancer, and is thus potentially available for ocular use by compounding pharmacies at a much lower cost than aflibercept. (29)

Repair of complicated vitreoretinal disease, such as RD, has conventionally been accomplished via 23-G pars plana vitrectomy (PPV) systems.(44)

Visual outcome after RD repair is not as high as the anatomic success rate especially in cases of macula-off RRD, where macula is detached. Many factors influence the visual outcome in these cases such as preoperative visual acuity, duration of detachment, age of patients, structural macular changes, and type of surgical technique.(6,1,22)

In this study, we studied outcome of RD repair in consecutive patient.

Material and method :

We conducted a retrospective review of the medical records of all surgical cases performed by a single vitreoretinal surgeon at Dar ALwafa clinic which is one of the four Private clinic in Tripoli that has been recently equipped for vitreoretinal surgeries, The covered period of this study was from January 2017 to December 2017.

Preoperative clinical findings were obtained from the assessment notes. This included age and gender of the patients, phakic status, and macula status ,patients underwent preoperative intravitreal bevacizumab (IVB)1 week before the surgery ,patient with dense vitreous haemorrhage had been done ultrasound US. Types of surgical techniques were also included.

Postoperative outcome and complications were obtained, too.

Patients with follow-up period of less than two weeks were excluded.

In patients with a preoperative visually significant cataract, cataract extraction and implantation of an acrylic, foldable intraocular lens was performed via phacoemulsification through a clear corneal incision.

The 23-G underwent vitrectomy by using the 23-G trocar-cannula system (Alcon Laboratories, Inc., Fort Worth, TX).

The conjunctiva and sclera were penetrated by a trocar 3.5 mm posterior to and in parallel with the limbus, depending on the lens status, at an angle between 20° and 30° with the bevel up, while inserting the cannula into the scleral incision.

Once the trocar sleeve was reached, the cannula was rotated perpendicular to the eyeball toward the posterior pole, The cannula was held in place with forceps and the trocar was removed, The intraoperative technologies used mainly included the stripping of membranes, intraocular diathermy, laser photocoagulation, trans-scleral cryotherapy, air-fluid exchange, in all cases triamcénolone (Kenacort 40mg) used to stain the vitreous , to aid visualization of the vitreous, which is help in removing the hole of vitreos and decrease the rate of redetached as post ppv complication , After removal of posterior hyaloid, 0.2 mL BBG was applied on the macula, to stain ERM under air conditions for 2 minutes.

Internal limiting membrane (ILM) was intensely stained and peeled in all cases following ERM removal., the ERM was also observed to be intensely stained with BBG and peeled with an ILM forceps, and air/silicone oil tamponade, microscope forceps were used to clip the incision after pulling the cannula out at the end of operation, and then an oppressor or cotton bud was used to massage the incision repeatedly.

The operations were performed under local or general anesthesia.

Primary outcome measures included postoperative best-correct visual acuity by the logarithm of the minimal angle of resolution (LogMAR) visual acuity (BCVA), postoperative intraocular pressure (IOP) measured by Goldmann applanation tonometry. and rates of postoperative complications including redetachment, vitreous hemorrhage, epiretinal membrane formation, ocular hypertension or hypotony, and endophthalmitis.

Result :

117 eyes from 117 patients were included in this study ,The mean age of all patients was 48.69 years (range 8 –75 years) .

males were 49.57%, females were 48.69%, one of our 117 patients was lost to follow-up.

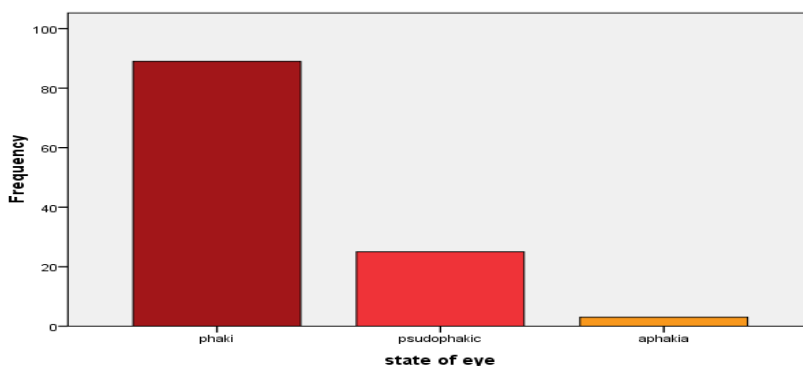
26 eyes were pseudophakic preoperatively, while the 88 eyes were phakic, 71 had a visually significant cataract that required extraction during the primary RD repair, while 3 cases surgically aphakic.

46 eyes we did for them ppv only, 3 of them were surgically aphakic, 20 patients were phakic, 23 cases were pseudophakia .

state of eye

		Frequency	Percent	Valid Percent	Cumulative Percent
Valid	Phaki	89	76.1	76.1	76.1
	Psudophakic	25	21.4	21.4	97.4
	aphakia	3	2.6	2.6	100.0
	Total	117	100.0	100.0	

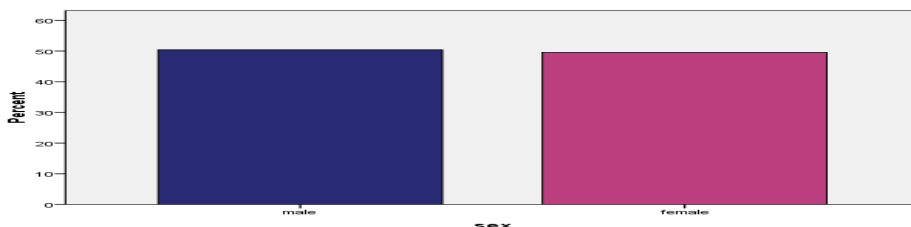
state of eye



Sex

		Frequency	Percent	Valid Percent	Cumulative Percent
Valid	Male	59	50.4	50.4	50.4
	Female	58	49.6	49.6	100.0
	Total	117	100.0	100.0	

sex



Nineteen out 117 eyes (16%) had a combined rhegmatogenous and tractional retinal detachment, and 50 of these eyes (42.7%) also had RRD 12 of them had

———— Surgical outcomes of 23-gauge pars plana vitrectomy for retinal detachment patients in Tripoli

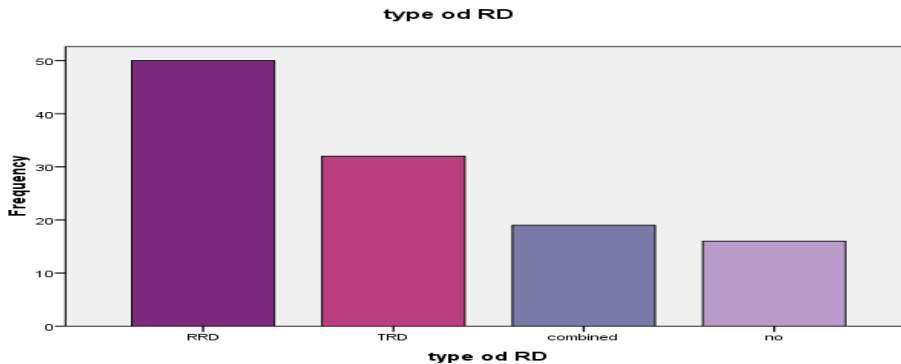
macula on ,30 candidates had macula off, PVRC3 present in 8 of them.

32(26.4%) patients had TRD ,20 of them with Vitreous .H,12 of them had TRD without vitreous H, where 16 cases had vitreous haemorrhage only.

Diabetes mellitus was the most common cause of retinal detachment (TRD, combined TRD/RRD), it was 62%(73 of cases), myopia was the second cause 31.6% (37 cases RRD), Trauma was 5% of them (7 cases only RRD).

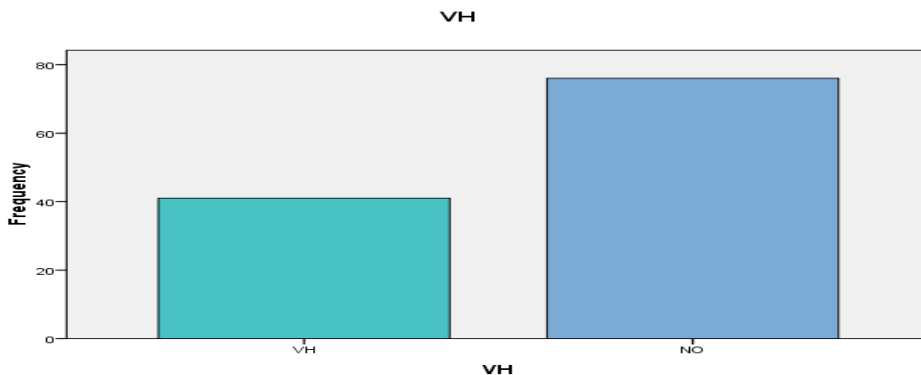
Type of RD

		Frequency	Percent	Valid Percent	Cumulative Percent
Valid	RRD	50	42.7	42.7	42.7
	TRD	32	27.4	27.4	70.1
	combined	19	16.2	16.2	86.3
	no	16	13.7	13.7	100.0
	Total	117	100.0	100.0	



VH

		Frequency	Percent	Valid Percent	Cumulative Percent
Valid	VH	41	35.0	35.0	35.0
	NO	76	65.0	65.0	100.0
	Total	117	100.0	100.0	



We did combined phacoemulsification and paras plana vitrectomy for 70 eyes, other 47 eyes we did for them only paras plana vitrectomy .

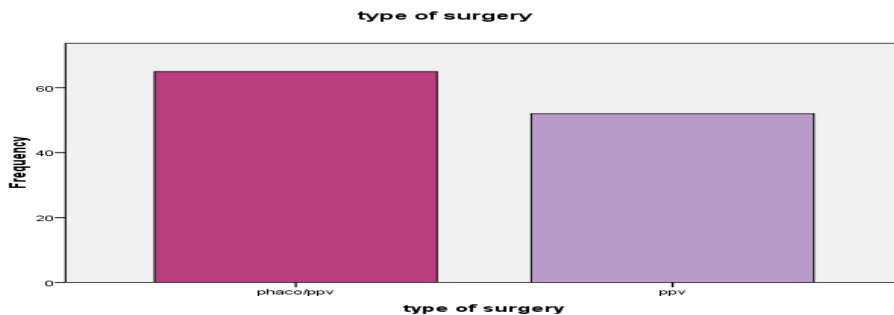
85 of our patient were tamponaded with silicon oil , 32of them with air.

38 eyes had preoperative intravitreal bevacizumab (IVB) ,average age 52 years old (24-75),24 of them were females,14 were males.

22 of cases were TRD with VH,7 cases had TRD without VH ,8 patients had a combined TRD/RRD , one patient had a combined with VH, Preoperative vitreous hemorrhage was present in 41eyes.

We injected TA in all cases to visualize the vitreous.

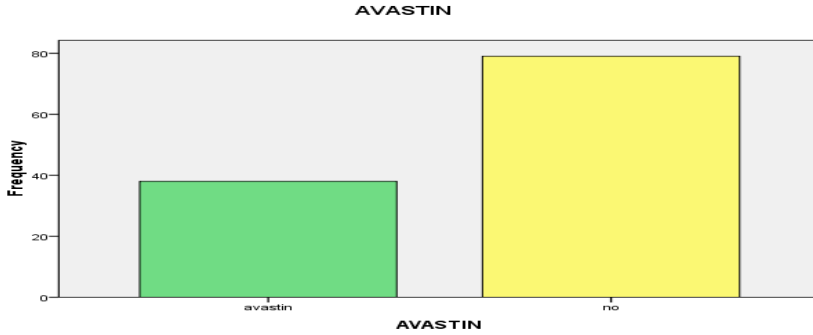
	Frequency	Percent	Valid Percent
phaco/ppv	70	81.9	81.9
ppv	47	54.9	54.9
Total	117	100.0	100.0



Surgical outcomes of 23-gauge pars plana vitrectomy for retinal detachment patients in Tripoli

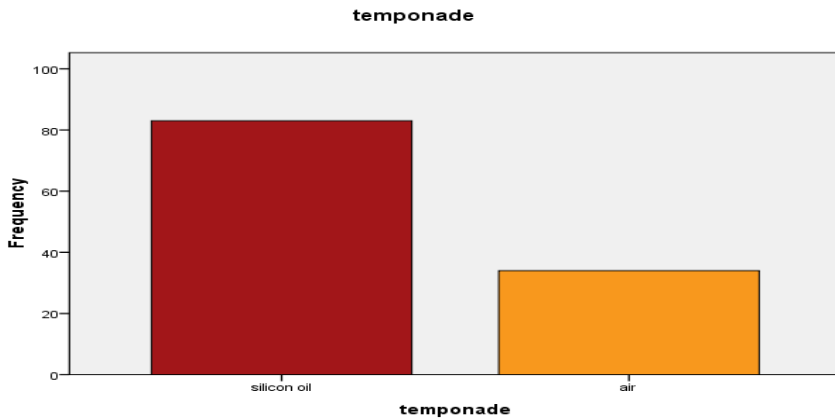
AVASTIN

		Frequency	Percent	Valid Percent	Cumulative Percent
Valid	avastin	38	32.5	32.5	32.5
	no	79	67.5	67.5	100.0
	Total	117	100.0	100.0	



The type of Temponade

		Frequency	Percent	Valid Percent	Cumulative Percent
Valid	silicon oil	83	70.9	70.9	70.9
	air	34	29.1	29.1	100.0
	Total	117	100.0	100.0	



Mean preoperative IOP was 11.16 mmHg (range 6–24 mmHg), which is increase post operative to be 12.58%, there was positive significant relation $p < 0.01$ between pre operative IOP and post operative IOP.

we had 4 patients known case of Glucoma on antiglucoma medication (cosopt eye drop), their IOP were controlled post operative.

we had 3 cases with IOP > 20 mmhg, and their IOP were controlled with antiglucoma medication (cosopt eye drop).

We had 5 patients their IOP > 40 mmhg, 2 of them had posterior psynachea, therefore we did for them eripheral iridectomy, their IOP decrease to normal level.

Other 3 cases had been removed the silicon oil within less than 2 month, One of these cases we did for her Ahmed valve to control her IOP.

the temponade was silicon oil in 7 of them, and was an air in one of them.

3 of them had TRD with VH, 3 of them had combined TRD/RRD, 1 of them had RRD, the last one of these cases had vitreous hamorage only.

IOP	N	Minimum	Maximum	Mean	Std. Deviation
IOP PRE OP	117	6.00	22.00	11.1624	2.69405
IOP POST OP	117	6.00	58.00	12.5812	7.79947

None of the eyes required an additional air tamponade or any other procedure in the early postoperative period due to hypotony.

2 cases had redetached retina, therefore we did for them another ppv, the two cases were highly myopic patients.

Postoperative visual acuity outcome is improve in 106 eyes, the same in 4 eyes, Worsened visual acuity was noticed in seven eyes (seven patients, 3 males and 4 female).

Their average age was 50 years, 3 of them had combined TRD/RRD, one of them had RRD with macula off, 2 of them had TRD and one of them had VH.

Mean BCVA logMARs were as follows: preoperatively 1.898,

postoperatively 1.076, we had positive significant relation $p < 0.01$ between preoperative BCVA and post operative BCVA.

Mean BCVA decreased significantly on postoperative first day and first week, mainly due to air or silicon oil tapenade, and increased significantly in the first month and final control in almost all of them.

2 of them had corneal oedema because of high IOP > 50 mmhg.

Anatomical success was obtained in 98% of the patients and functional success in 85%.

VA	N	Minimum	Maximum	Mean	Std. Deviation
VA PRE OP	117	0500.	2.7000	1.898E0	7956092.
VA POST OP	117	0500.	2.7000	1.076E0	6231722.

Causes of post-operative visual reduction

Reason	Number of patient
High IOP	10
Macular oedema	2
Re-detached	2

Discussion :

This study is the first study done to assess the outcome of RD repair by using 23-G PPV among our patient , We included 117 consecutive patients.

There was no significant difference between right and left eyes in terms of incidence of RD, RRD represented in 42.7% of our patient with macula-off represented 25% of them, where 10% of them with macula on .

patient with TRD represented in 26% ,another 19 patients had a combined TRD/RRD.

More than half of the patients (75%) were phakic and rest were either pseudophakic (22%) or aphakic (2%). This finding is similar to a previous study in literature, in which a population of patients of RD was studied.(14) In that study, phakic eyes constituted 55%, pseudophakic 35%, and aphakic

10%. However, it is known that aphakia and pseudophakia status are risk factors for development of RRD.(2)

Age is risk factor for RRD.(37,10,40,20,41,42) , Our result showed 66% of the patient were older than 40 years of age. there was one patient who was 8 years old with high myopia , where the diabetes mellitus is the risk factor in TRD in our study 62% of the patient had diabetes mellitus.(19,39)

the amount of improvement in logMAR visual acuity was found in our current study. Koh et al. conducted a study to explore the effectiveness and safety of 23-G vitrectomy, revealing the preoperative and postoperative mean logMAR visual acuity was 1.898 and 1.076, respectively; that is, the mean logMAR visual acuity was improved by 23-G vitrectomy . (42)

Among patients with air tamponade, mean postoperative visual acuity was lower on day 1 and in week 1, and BCVA was assessed after tamponade resorption. On postoperative follow-up, mean visual acuity at month 1 was elevated as compared with the preoperative value, and the elevation continued on last follow-up, Other studies about 23G vitrectomy also reveal a statistically significant increase in postoperative follow-up visual acuity values when compared with those in the preoperative stage.(29,23,30)

a significant increase in postoperative visual acuity was identified in all patients in general.

We do not had hypotony as a complication of 23G vitrectomy among our study , After started to use 23G vitrectomy, Eckardt stated that the angle of the incision is more important than its size in preventing postoperative hypotony. (7,3,14,38,34)

We had high IOP in 8 patient ,7 of them the temponade was silicon oil ,one of the with air , we did for 3 of them silicon oil removal within less than 2 month , we did shunt for one of cases(Ahmed valve)after silicon oil removed, 2 of them had been done peripheral ireductomy to control ther IOP due to the presence of post synachea.

We did peripheral retinectomy for 2 of our patient, they were higly myopic. in our study, intravitreal bevacizumab was used as a preparatory

preoperative step to reduce the risk of intraoperative bleeding and thus to improve the intraoperative conditions for the surgeon, The recent use of preoperative intravitreal injection of bevacizumab (IVB) (Avastin, Genentech Inc., South San Francisco, CA, USA) may potentially further improve diabetic vitrectomy outcome.

This vascular endothelial growth factor inhibitor has been reported to decrease intraoperative hemorrhage and facilitate fibrovascular membrane dissection(44).

preoperative IVB made TRD surgery more efficacious, especially in younger diabetic patients.(16)

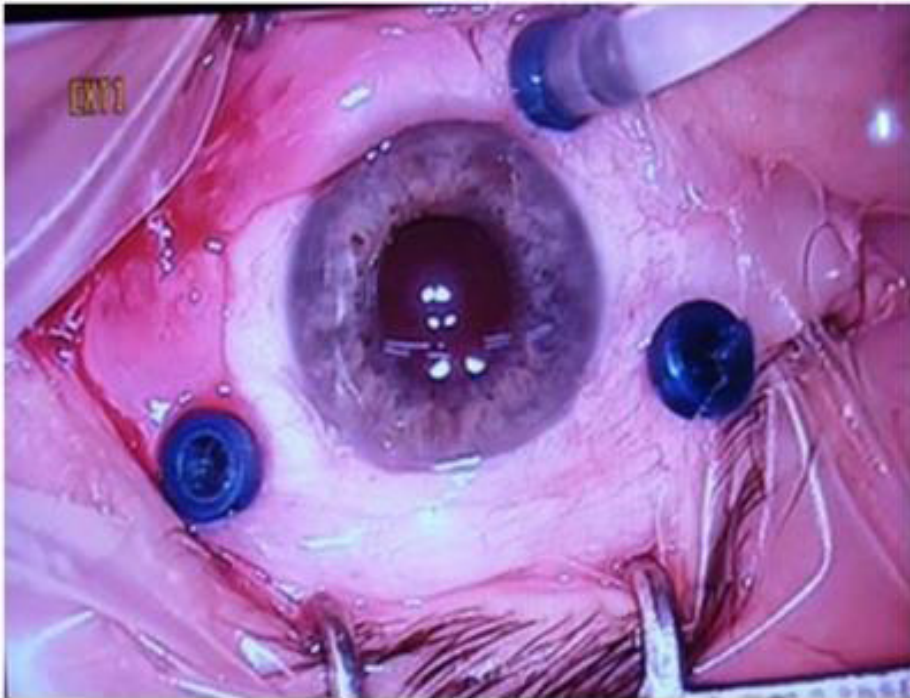
we injected TA in all cases to visualize the posterior hyaloid which is help in removing the hole membrane also , The intra-operative use of TA visualizes the posterior hyaloid clearly, which facilitates its removal (8) , as the residual posterior hyaloid can act as a scaffold for pre-retinal fibrous-membrane formation, its removal could reduce the incidence of post-operative pre-retinal fibrosis .(11)

ILM that persists after ERM peeling acts as a scaffold for cell proliferation, leading to ERM recurrence. In a previous study, Shimada et al.³⁵ found that BBG has low affinity to ERM and recommended the reapplication of BBG after ERM peeling to remove the residual ILM to reduce the risk of ERM recurrence, for that we used BBG and we had only 2 re detached and need another repair .(35,38,40)

This study provided a better option of 23-G vitrectomy for clinically managing RD. However, with our own difficulty during the study , the study was retrospective because of that we lost the patients data , we lost the contact with one patient after first post operative follow up.

Secondary the size of sample was small, it did not include the all Libyan area ,because of that we dropout some criteria.

Further studies with bigger number of patients in other centers all over the country are recommended to study more criteria we might not include in our study.



Trocar and infusion canula positions in 23 gauge vitrectomy.



Referance:

1. Anti-vascular endothelial growth factor for proliferative diabetic retinopathy. *Cochrane Database Syst Rev* 2014; 11.
2. A review of anti-VEGF agents for proliferative diabetic retinopathy. *Eye (Lond)* 2014; 28:510–520.
3. a novel angiogenesis inhibitor for the treatment of metastatic colorectal cancer. *Am J Health Syst Pharm.* 2013;70(21):1887–1896.
4. Association between severity of vitreous haemorrhage and visual outcome in primary rhegmatogenous retinal detachment. *Acta Ophthalmol.* 2008;86:165–9.
5. Avastin as an adjunct to vitrectomy in the management of severe proliferative diabetic retinopathy: a prospective case series. *Clin Experiment Ophthalmol.* 2008;36:449–454.
6. Can a preoperative bevacizumab injection prevent recurrent postvitrectomy diabetic vitreous haemorrhage. *Eye.* 2009;23:1698–1701.
7. Comparative study of 23-gauge vitrectomy versus 20-gauge vitrectomy for the treatment of rhegmatogenous retinal detachment. *Graefes Arch Clin Exp Ophthalmol.* 2011;249:1459–68.
8. Complications of vitreous surgery for diabetic retinopathy. I. Intraoperative complications. *Ophthalmology* 1983; 90:517–521.
9. Double staining with brilliant blue G and double peeling for epiretinal membranes. *Ophthalmology* 116, 1370–376 (2009).
10. Diabetic retinopathy. *Lancet* 2010; 376:124–136.
11. Double staining with brilliant blue G and double peeling for epiretinal membranes. *Ophthalmology* 116, 1370–376 (2009).
12. Evidence-based medicine regarding the prevention of retinal detachment. 1999;97:397–404. Transactions of the American Ophthalmological Society.
13. Future perspectives in primary retinal detachment repair. *Eye (Lond)* 2002;16:349–52.
14. Incidence of endophthalmitis after 20-gauge vs 23-gauge vs

- 25-gauge pars plana vitrectomy. *Graefes Arch Clin Exp Ophthalmol*. 2011;249:377–80.
15. Long-term evaluation of anatomic and functional results after complicated retinal detachment treated with pars plana vitrectomy and heavy silicone oil tamponade. *Klin Monbl Augenheilkd* 2009; **226**: 707–712.
16. Laser treatment of diabetic retinopathy. *Dev Ophthalmol* 2007; 39:48–68.
17. Outcomes of 23-gauge pars plana vitrectomy in vitreoretinal diseases 2011 Dec 14
18. Office-based sutureless transconjunctival pars plana vitrectomy. *Retina*. 2002;22:725–32.
19. Outcomes of vitrectomy for tractional retinal detachment in diabetic retinopathy. *Int Ophthalmol Clin*. 2014;54:127–39.
20. Outcomes of 77 consecutive cases of 23-gauge transconjunctival sutureless vitrectomy for posterior segment disease. *Ophthalmology*. 2007;114:1197–1200.
21. Pars plana vitrectomy techniques for relief of epiretinal traction by membrane segmentation. *Am J Ophthalmol*. 1980;89(3):408–413.
22. Progression of tractional retinal detachment following intravitreal bevacizumab. *Acta Ophthalmol* 2009; 87:571–572.
23. Preclinical investigation of internal limiting membrane staining and peeling using intravitreal brilliant blue G. *Retina* 26, 623–30 (2006).
24. Pneumatic retinopexy. A two-step outpatient operation without conjunctival incision. *Ophthalmology*. 1986;93:626–41.
25. Predictive visual outcome after macula-off retinal detachment surgery using optical coherence tomography. *Retina*. 2005;25:44–53.
26. Pars plana vitrectomy assisted by triamcinolone acetonide for refractory uveitis: a case series study. *Br J Ophthalmol* 87:1010–1014
27. Possible benefits of triamcinolone-assisted pars plana vitrectomy for retinal diseases. *Retina* 23:764–770
28. Recent trends in the management of rhegmatogenous retinal

- detachment. *Surv Ophthalmol.* 2008;53:50–67.
29. Reduced incidence of intraoperative complications in a multicenter controlled clinical trial of triamcinolone in vitrectomy. *Ophthalmology* 114:289–296.
 30. Residual internal limiting membrane in epiretinal membrane surgery. *Br J Ophthalmol* 93, 1016–1019 (2009).
 31. Retinal detachment. *Clin Evid (Online)* 2008:2008.
 32. Retinal detachment A study of a population-based patient material in Sweden 1971 – 1981. I *Epidemiology Acta Ophthalmol (Copenh)* 1987;65:213–22
 33. Silicone oil for the treatment of severe proliferative diabetic retinopathy. *Ophthalmology.* 1989;96(6):759–764.
 34. Sutureless 23-gauge versus 20-gauge vitrectomy with silicone oil injection in rhegmatogenous retinal detachment. *Retina.* 2012;32:1013–6.
 35. Surgical outcomes of 23-gauge vitrectomy for the management of lens fragments dropped into the vitreous cavity during cataract surgery. *Saudi J Ophthalmol.* 2014;28:253–6.
 36. Transconjunctival sutureless 23-gauge vitrectomy. *Retina.* 2005;25:208–11.
 37. Triamcinolone acetonide as an aid to visualization of the vitreous and the posterior hyaloid during pars plana vitrectomy. *Retina* 20:554–555
 38. Twenty-three-gauge and 20-gauge vitrectomy in epiretinal membrane surgery. *Retina.* 2010;30:112–6.
 39. 25-, 23-, and 20-gauge vitrectomy in epiretinal membrane surgery: a comparative study of 553 cases. *Graefes Arch Clin Exp Ophthalmol.* 2011;249:1811–9.
 40. 25-gauge, sutureless vitrectomy and standard 20-gauge pars plana vitrectomy in idiopathic epiretinal membrane surgery: a comparative pilot study. *Graefes Arch Clin Exp Ophthalmol.* 2006;19:1–8.
 41. Transconjunctival 23-gauge sutureless vitrectomy. *Retina.* 2005;25:208–211.

42. two-step outpatient operation without conjunctival incision. *Ophthalmology*. 1986;93:626–41.
43. The correlation between height of macular detachment and visual outcome in macula-off retinal detach
44. ments of $<$ or $=7$ days' duration. *Ophthalmology*. 2005;112:1213–7.
45. Use of intravitreal bevacizumab as a preoperative adjunct for tractional retinal detachment repair in severe proliferative diabetic retinopathy. *Retina*. 2006;26:699–700.

نتائج عمليات اصلاح الانفصال الشبكي باستخدام تقنية 23 قيج وإزالة الجسم الزجاجي للمرضى الليبيين

■ د.خليفة محمد السويدي * ■ د.رانيا مسعود الرجباني **

الهدف :

متابعة و تقييم نتائج العمليات و كذلك مضاعفاتها باستخدام تقنية 23 قيج لاصلاح الانفصال الشبكي باستعمال الجراحه الدقيقة بدون استخدام غرز .

الطريقة :

بالاطلاع على سجلات المرضى الذين أجريت لهم عمليات إصلاح الانفصال الشبكي باستخدام 23 قيج خلال الفتره من يناير 2017 إلى ديسمبر 2017 حيث تم استخدام زيت السيلكون و الهواء لتثبيت الشبكية بعد العملية و كان متوسط اعمار الحالات 48 . 69 سنة و تم تسجيل قوة الابصار للمرضى قبل اجراء العملية وكذلك قياس ضغط العين و تسجيل النتائج من خلال الكشف على المرضى .

النتائج :

أُجريت 117 عملية إصلاح انفصال شبكي لعدد متساو من الإناث و الذكور لمعدل اعمار 48 - 69 سنة و كانت نسبة النجاح باستخدام عملية واحدة فقط كان 98 % و نسبة تحسن الرؤيه بعد العملية كانت 89.74 % .

معدل ضغط العين ارتفع من 11.6 الى 12.58 .

عدد عشرة مرضى عانوا من ارتفاع ضغط العين بعد العملية و تمت معالجتهم .
لم تسجل اية حالة التهاب أو عدوى بعد العملية و تم متابعة الحالات حتى 32 اسبوعا بعد العملية .

الخلاصة:

استخدام الجهاز الجراحي لإصلاح الشبكية المعتمد علي 23 قيج يعتبر فعالا جدا في إصلاح جميع أنواع الانفصال الشبكي و كذلك خاليا من المضاعفات .

* عضو هيئة تدريس كلية الطب جامعة طرابلس استشاري طب و جراحة الشبكية بمستشفى العيون طرابلس.

** إخصائية طب و جراحة العيون مستشفى العيون طرابلس .