

Immunohistochemical expression of proliferating cell nuclear antigen (PCNA) in the parotid salivary glands of male albino rats after long administration of nutmeg

El-Sakhawy M.A*; Abusaida H**, Issa Y**, Al-Sabaa A***and Abdelgayed Sh***

Abstract

A total number of 60 adult male albino rats (average weight = 200gm) were used and were classified into two main groups:

1. The Control group (Group A): comprised 20 animals. These animals received 1ml of distilled water orally on a daily basis for the duration of the experiment (2, 4, 6 and 8 weeks).

2. The Experimental group (Group B): comprised 40 animals and was subdivided into 4 subgroups corresponding to 4 durations (2, 4, 6 and 8 weeks). Each subgroup in turn was further divided into 2 subgroups in which each rat was given 1ml of the prepared nutmeg aqueous extract orally on a daily basis in the following doses (100 and 500 mg/kg b.w.) respectively. On termination of the experiment, the parotid salivary glands were dissected out, cleaned and fixed in 10% buffered formalin solution. Then, paraffin wax sections were obtained and stained with: Haematoxylin and Eosin (H&E) to verify histological details. Other paraffin sections were prepared and stained immunohistochemically for the expression of PCNA.

The parotid gland of the control group (Group A) was composed of parenchyma which showed normal appearance of secretory acini and ducts; and fine C.T. stroma in between lobes and lobules.

* *Department of Cytology & Histology, Faculty of Veterinary Medicine, Cairo University, Egypt*

** *Department of Histology & Human Genetics, Faculty of Medicine, Tripoli University, Libya*

*** *Department of Pathology, Faculty of Veterinary Medicine, Cairo University, Egypt*

As for the experimental group (Group B), the most noticeable changes were cytoplasmic vacuolations in acinar cells, dilatation of intercalated and striated ducts, congestion of blood vessels, signs of nuclear changes (pyknosis, karyolysis, karyorrhexis, hyperchromatism, etc.), lymphocytic infiltration, hyalinization of C.T. stroma. These changes gradually increased as the duration increased and as the dose administered increased.

PCNA Immunohistochemical results showed weak +ve PCNA in the nuclei of the acini. In the experimental groups, the nuclei of the acinar cells revealed moderate +ve PCNA expression in subgroups 1 and 2, while in subgroups 3 and 4 both the nuclei of the acinar cells and the ducts revealed intense +ve PCNA expression. The cytoplasm of the acinar cells also showed weak +ve PCNA expression in subgroups 3 and 4.

Image analysis results revealed significant increase in the blue binary colour in the experimental groups with the increase of duration and with the increase of the dose of nutmeg extract as well.

Key words: *Nutmeg, Parotid, PCNA, Myristica fragrans Houtt.*

Introduction:

The nutmeg tree (*Myristica fragrans* Houtt.) is a tropical aromatic evergreen tree that yields an apricot-shaped fruit. Contained in the fruit is a nutmeg seed covered by a protective layer or aril. The seed is processed to make nutmeg and the aril can be processed into a spice called mace [Kisby, 2003].

Nutmeg is a common household spice and is frequently used in cooking and baking. Recently, nutmeg has become popular among individuals seeking legal and natural hallucinogenic and euphoric experiences. Available forms of nutmeg include the whole nut, ground powder, and volatile oils [Kisby, 2003].

Besides nutmeg and mace, a number of other products, namely oleoresin, nutmeg butter and essential oils, are also derived from *M.fragrans*. These products find varied use in the food, medicine and perfume industries [Leela, 2008].

With the recent gain in popularity of herbal medicine all over the world, it is also possible to abuse the use of *M.fragrans* because of its medicinal

_____ Immunohistochemical expression of proliferating cell nuclear antigen (PCNA) properties. It has been reported that the spice can be toxic when ingested in large quantities causing convulsions, hallucinations, and possibly death. The medicinal use of nutmeg and its use as a spice suggest that it contains some constituents which are responsible for the reported biological activities. Some of these active principles may at the same time possess some adverse effects [Olaleye, *et al.*, 2006].

The principal constituents of nutmeg are fixed oil, volatile oil and starch. Nutmeg is reported to contain moisture, 14.3%; protein, 7.5%; ether extract, 36.4%; carbohydrates, 28.5%; fiber, 11.6%; and mineral matter, 1.7%; calcium, 0.12%; phosphorus, 0.24%; and iron, 4.6mg/100g.

It contains volatile oil (6-16%); starch (14.6-24.2%); pentosans (2.25%); furfural (1.5%); and pectin (0.5-0.6%). It is only a fair source of vitamins [Leela, 2008].

The fixed oil contains myristin and myristic acid. The volatile oil contains pinene, sabinene, camphene, myristicin, elemicin, isoelemicin, eugenol, isoeugenol, methoxyeugenol, safrole, dimericphenylpropanoids, lignans and neolignans [Malviya, Jain, Gupta, & Vyas, 2011].

Phytochemical screening of aqueous extract of the seed of *M.fragrans* revealed the presence of alkaloids, saponins, anthraquinones, cardiac glycosides, flavonoids and phlobatanins while tannins were absent. [Olaleye, *et al.*, 2006].

Proliferating cell nuclear antigen (PCNA) is a monoclonal antibody that allows the study of cell kinetics [Mattioli, *et al.*, 2011].

PCNA is a non-histone nuclear protein that functions as a cofactor for DNA polymerase-delta and plays a role in the initiation of cell proliferation [Rivero, *et al.*, 2004].

PCNA is present in very small amounts in normal non-dividing cells (senescent and quiescent cells included) and tissues, but is synthesized by proliferating cells of both normal and transformed origin, including tumors [Madsen & Celis, 1985].

The presence of functional PCNA is critical for cell survival because of all of its functions: DNA replication, DNA repair and probably DNA recombination processes [Paunesku, *et al.*, 2001].

PCNA exerts a tripartite function by operating as (1) a sliding clamp during DNA synthesis, (2) a polymerase switch factor and (3) a recruitment factor. Most of its functions are mediated by its interactions with various proteins involved in DNA synthesis, repair and recombination as well as in regulation of the cell cycle and chromatid cohesion [Strzalka & Ziemienowicz, 2011].

This protein has a high concentration in the late G₁ and early S phases, diminishes in the G₂ phase and is almost absent in the M phase [Cardoso, Denardum, Rapoport, Araujo, & Carvalho, 2000].

Some researches were done to study the various effects of nutmeg on different organs such as the kidney, liver, spleen, heart, testes, brain, etc. But no studies were done on any oral tissues. That's why our study was done to try to participate in more understanding of the effect of nutmeg administration in different durations and in different doses on the histology and immunohistochemistry of the parotid salivary gland of male albino rats.

Materials and methods

Animals:

A total number of 60 adult male albino rats (average weight = 200gm) were used in this study. The animals were housed in cages at the Faculty of Veterinary Medicine, Cairo University, under the optimal experimental conditions. They were kept at room temperature 22-24°C. Animals were fed on ground barley and supplied water ad-libitum.

The animals were classified into two main groups:

- I. The Control group (Group A): comprised 20 animals. These animals received 1 ml of distilled water orally on a daily basis for the duration of the experiment (2, 4, 6 and 8 weeks).
- II. The experimental group (Group B): comprised 40 animals. This group in turn was subdivided into 4 subgroups (10 animals each):
 - a. Subgroup 1: was subdivided into 2 subgroups (5 animals each). These animals were given 1 ml of nutmeg extract orally on a daily basis for 2 weeks in doses: of 100 (1a) and 500 (1b) mg/kg b.w. respectively.
 - b. Subgroup 2: was subdivided into 2 subgroups (5 animals each). These animals were given 1 ml of nutmeg extract orally on a daily basis for 4 weeks

_____ **Immunohistochemical expression of proliferating cell nuclear antigen (PCNA)** in doses of 100 (2a) and 500 (2b) mg/kg b.w. respectively.

c. Subgroup 3: was subdivided into 2 subgroups (5 animals each). These animals were given 1 ml of nutmeg extract orally on a daily basis for 6 weeks in doses of 100 (3a) and 500 (3b) mg/kg b.w. respectively.

d. Subgroup 4: was subdivided into 2 subgroups (5 animals each). These animals were given 1 ml of nutmeg extract orally on a daily basis for 8 weeks in doses of 100 (4a) and 500 (4b) mg/kg b.w. respectively.

Preparation of the Nutmeg seed's extract

Nutmeg seeds were obtained from Egyptian local markets and botanically identified through herbarium staff and a voucher specimen was deposited at the herbarium of Botany and Microbiology (Department, Faculty of Science, Minia University, Minia, Egypt). The dry seeds were washed thoroughly to remove dust, fungal spores and / or other undesired particles, then left to dry under room temperature overnight. The seeds were then macerated into a fine flour-like paste using a mortar and pestle to pass through 0.2 mm mesh. Aliquot weight of nutmeg powder (125 gm) was soaked in 500 ml hot distilled water and left to stand for 72 hrs. then filtered the extract. The extract was kept frozen until used. Doses of 100, 300 and 500 mg nutmeg extract were prepared as outlined by Olaleye *et al.*, [2006].

Histological procedures:

On termination of the experiment, the animals were humanely sacrificed under anaesthesia. Ethical guidelines for use of animals in scientific research were carefully followed throughout this experiment [Tandon, *et al.*, 2000]. Animals were anaesthetized by diethyl ether [(C₂H₅)₂O] inhalation.

Then the parotid salivary glands were dissected out, cleaned rapidly of any adherent connective tissue and fixed immediately in 10% neutral buffered formalin solution. Then, the specimens were washed by tap water, dehydrated in ascending grades of ethyl alcohol, cleared in xylol and embedded in paraffin wax. Sections of 6-7 μ thick were obtained and mounted on clean glass slides and stained with: Haematoxylin and Eosin (H&E) to verify histological details, [Drury & Wallington, 1980]. Additional sections were prepared for PCNA immunohistochemical staining [Ramos-Vara, 2005].

Immunohistochemical examination for detection of PCNA:

Immunohistochemistry was performed on paraffin sections, and mounted on coated glass slides. Antigen was retrieved in citrate buffer (pH 6.0) microwave digestion (2 cycles of 12 minute each). Endogenous peroxidase was blocked with 0.05% hydrogen peroxide for 30 min. After incubation with a 1:20 dilution of normal horse serum, the slides were incubated overnight at 4°C with primary antibodies (Dako, 1:50). Secondary antibodies associated with a streptavidin-biotin-peroxidase method were applied (Dako A/S). Di-aminobenzidine was used as chromogen. All sections were counter-stained with haematoxylin. The sections were washed with phosphate buffered saline after each step. Negative controls were used using non-immune serum instead of the primary or secondary antibodies. The method used was outlined according to [Ramos-Vara, 2005].

Evaluation of immunostains:

Immunohistochemically stained sections were examined using Leica Quin 500 analyser computer system (Leica Microsystems, Switzerland) in Faculty of Dentistry, Cairo University. The image analyser is calibrated automatically to convert the measurement units (pixels) produced by the image analyser program into actual micrometre units. PCNA immunostaining was measured as area % in a standard measuring frame in six fields in each group using magnification (x400) by light microscopy transferred to the screen. The areas showing PCNA +ve brown immunostaining were chosen for evaluation, regardless the intensity of staining. These areas were masked by a blue binary colour to be measured by the computer system (**Fig.1**). Mean value and standard deviation were obtained for each specimen.

Statistical analysis:

Data related to the area percent (area %) of PCNA immunoreactivity were presented as mean and standard deviation (SD) values. Analysis of variance (ANOVA) test was used to detect statistical significance of the difference between all groups. Student's t-test was used for comparisons between two groups. The significance level was set at $P \leq 0.05$. Calculations were made using Statistical Package for Social Sciences (SPSS) software version 15.0 for Windows.

Results

Histological and histopathological results

Examination of control group sections of parotid salivary glands revealed that, the gland consisted of secretory acini and ducts. These serous acini appeared round and had a narrow lumen. The acini were lined by pyramidal cells with apical acidophilic cytoplasm. Their nuclei were prominent, deeply stained, spherical in shape and basally situated (**Fig.2**). The duct system presented intercalated, striated and excretory ducts. The intercalated ducts were hardly identified, as they were compressed between the acini. The striated ducts were lined by a single layer of columnar cells which showed well defined outlines and central, rounded, darkly stained nuclei. The cytoplasm appeared eosinophilic and showed basal striation. Thick fibrous connective tissue was present between the lobes and lobules of the parotid glands.

Histopathological changes in the parotid salivary glands of experimental groups revealed hydropic degeneration of the cytoplasm. There were ill-distinct cell boundaries and vacuolization in the acini. The intercalated, striated and interlobular ducts were dilated and their cytoplasm showed complete signs of degeneration (**Fig.3**). The nuclei of the acinar cells showed signs of atypism, hyperchromatism and abnormal mitosis (**Fig.4**). The connective tissue stroma, both intra and interlobular revealed increase in collagen fiber thickness and showed hyalinization and lymphocytic infiltration (**Fig.5**). All blood vessels were dilated and engorged with blood (**Fig.6**). Some acini were completely ruptured so that the nuclei were expelled out of the acini. There was a prominent interacinar edema. These changes were more prominent as the dose increased and the duration was prolonged.

PCNA Immunohistochemical Results:

Immunohistochemical examination of the parotid salivary gland of the control group stained with PCNA, showed some nuclei of the acini revealing weak +ve immune reaction for PCNA (**Fig.7**).

Immunohistochemical examination of the parotid salivary gland of the experimental subgroups (1a, 1b, 2a&2b) stained with PCNA, showed the nuclei of the acinar cells revealing moderate +ve immune expression of PCNA

(Fig.8).

With advance of the experiment and administration of nutmeg, the nuclei of the acinar cells of the experimental subgroups (3a, 3b, 4a &4b) showed intense +ve immune reaction for PCNA (Fig.9). Also the cytoplasm of the acinar cells revealed weak +ve immune reaction for PCNA. Nuclei of the epithelium lining the ducts revealed intense +ve immune expression of PCNA (Fig.9).

Image analysis:

Table (1) showed the mean values of area % of PCNA and standard deviation of the control group and the studied experimental groups.

On measuring the area % of PCNA, the control group (group A) showed a small value when compared to the experimental group (group B). (Fig.10).

Significant increase in the blue binary colour was observed in the experimental groups with the increase of duration. This was obvious when comparing experimental subgroups (1a, 2a, 3a and 4a) with each other as shown in (Table 2). Also, the experimental subgroups (1b, 2b, 3b and 4b) were compared with each other and showed a significant increase, revealed in (Table 3). Comparison of means was performed by one-way analysis of variance (ANOVA) (Table 2 & 3). $P \leq 0.05$ was considered to indicate a statistically significant difference.

Significant increase in the blue binary colour was also detected in the experimental groups with the increase of the dose of nutmeg extract. This was clear when comparing experimental subgroup (1a) with experimental subgroup (1b) (Table 4). It was also obvious when comparing experimental subgroup (2a) with experimental subgroup (2b) (Table 5), experimental subgroup (3a) with experimental subgroup (3b) (Table 6) and experimental subgroup (4a) with experimental subgroup (4b) (Table 7). Student's t-test was used for comparisons between each two subgroups within the same experimental group (Table 4-7). It was obvious from the previous data that PCNA immunoexpression increased as the dose increased and also as the duration increased. In other words, PCNA immunoexpression was found to be dose - dependent and time - dependent. (Fig. 10)

Immunohistochemical expression of proliferating cell nuclear antigen (PCNA)

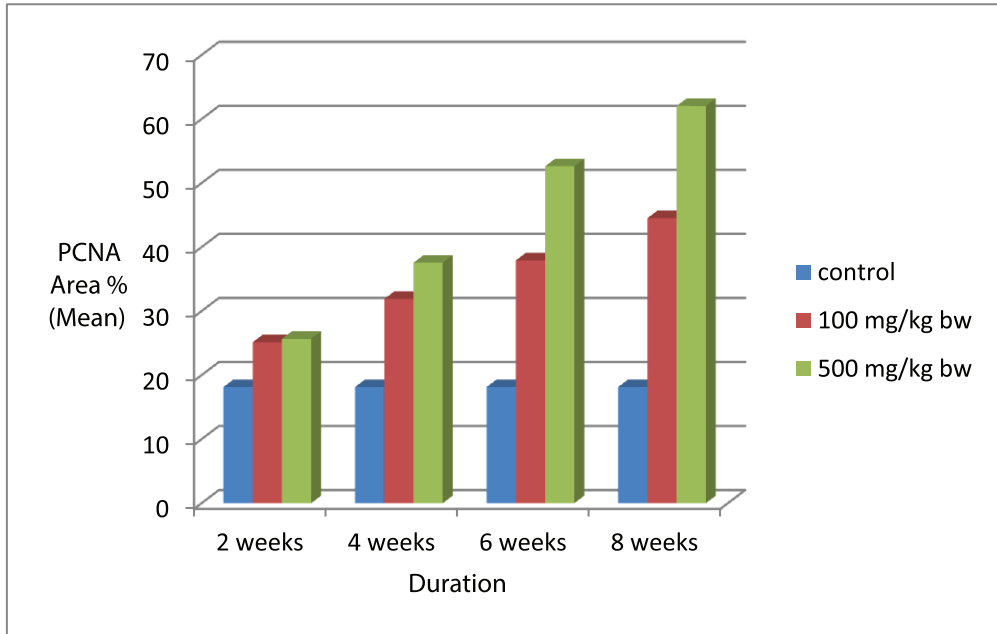


Figure (10): Comparison between mean values of area % of PCNA of control group (group A) and experimental subgroups (1a & 1b, 2a & 2b, 3a & 3b and 4a & 4b).

Table 1: Mean values of area % of PCNA and std. deviation of control group (group A) and the studied experimental subgroups

Group	Mean	Std. Deviation
Control (Group A)	18.15	3.019917
Group B (subgroup 1a)	25.14333	4.213647
Group B (subgroup 1b)	25.68	6.835776
Group B (subgroup 2a)	31.90333	4.043953
Group B (subgroup 2b)	37.56333	3.207739
Group B (subgroup 3a)	37.92333	2.47347
Group B (subgroup 3b)	52.625	4.361383
Group B (subgroup 4a)	44.52667	2.911968
Group B (subgroup 4b)	62.04833	1.748622

Table 2: Comparison between experimental subgroups (1a, 2a, 3a and 4a) using one-way ANOVA. * (highly significant)**

ANOVA

		Sum of Squares	df	Mean Square	F	Sig.
gp1a	Between Groups	1235.899	3	411.966	28.194	.000
	Within Groups	292.236	20	14.612		***
	Total	1528.135	23			

Table 3: Comparison between experimental subgroups (1b, 2b, 3b and 4b) using one-way ANOVA. * (highly significant)**

ANOVA

		Sum of Squares	df	Mean Square	F	Sig.
gp1c	Between Groups	4648.128	3	1549.376	72.590	.000
	Within Groups	426.881	20	21.344		
	Total	5075.009	23			

Table 4:): Comparison between experimental subgroups (1a and 1b) using student's t-test.ns (non-significant)

Independent Samples Test

		t-test for Equality of Means						
		t	df	Sig. (2-tailed)	Mean Difference	Std. Error Difference	95% Confidence Interval of the Difference	
							Lower	Upper
gp1a	Equal variances assumed	-.159	10	.877	-.53667	3.36733	-8.03955	6.96622
	Equal variances not assumed	-.159	8.775	.877	-.53667	3.36733	-8.18401	7.11068

Table 5: Comparison between experimental subgroups (2a and 2b) using student's t-test. (*significant)

Independent Samples Test

		t-test for Equality of Means						
		t	df	Sig. (2-tailed)	Mean Difference	Std. Error Difference	95% Confidence Interval of the Difference	
							Lower	Upper
gp2a	Equal variances assumed	-2.452	10	.034*	-5.66000	2.30838	-10.80340	-.51660
	Equal variances not assumed	-2.452	9.507	.035*	-5.66000	2.30838	-10.83974	-.48026

Table 6: Comparison between experimental subgroups (3a and 3b) using student's t-test. (*) highly significant)**

		Independent Samples Test							
		t-test for Equality of Means						95% Confidence Interval of the Difference	
		t	df	Sig. (2-tailed)	Mean Difference	Std. Error Difference			
gp3a	Equal variances assumed	-6.556	10	*** .000	-14.70167	2.24231	-19.69784	-9.70549	
	Equal variances not assumed	-6.556	7.915	.000	-14.70167	2.24231	-19.88214	-9.52119	

Table 7: Comparison between experimental subgroups (4a and 4b) using student's t-test. (*) highly significant)**

		Independent Samples Test							
		t-test for Equality of Means						95% Confidence Interval of the Difference	
		t	df	Sig. (2-tailed)	Mean Difference	Std. Error Difference			
gp4a	Equal variances assumed	-11.587	10	*** .000	-17.47667	1.50833	-20.83744	-14.11590	
	Equal variances not assumed	-11.587	8.058	.000	-17.47667	1.50833	-20.95051	-14.00283	

Discussion

The current study revealed varying changes in the glandular architecture including changes in the acini, ducts, connective tissue stroma and blood vessels. These changes varied from one group to another according to the dose administered and the duration of administration of nutmeg extract.

One of the prominent features of this study is vacuolisation. Rats given the lowest dose of nutmeg extract (100 mg/kg b.w.) and started to show vacuoles in their acinar cells at about 4 weeks. However, in rats taking the highest dose of nutmeg extract (500 mg/kg b.w.), vacuoles were obvious earlier at the first duration (2 weeks).

We noticed in our study that the extent of vacuolisation increased as the duration increased, which coincided with [Leslie & Putney, 1983] who stated that the extent of vacuolisation was time-dependent.

The vacuolations observed in the stroma of the superior colliculus in the

previous experiment were due to nutmeg interference, since it had been reported that myristicin obtained from the nutmeg had cytotoxic effects on the body [Adjene J. O., 2010].

Rats in the treated groups of another study also on rat brain, showed some cellular degenerative changes like hypertrophy, sparse cellular population, pyknotic nuclei with some microcystic changes, and vacuolation in the stroma of the treated medial geniculate body relative to those in the control [Adjene *et al.*, 2010].

The vacuolation process has to be seen as the visible response a cell makes in an attempt to maintain its functional status under stress [Henics & Wheatley, 1999].

Dilatation of the ducts was one of the prominent findings in our study. Both the intercalated and striated ducts were dilated in all experimental groups.

Scott *et al.*, [1999] studied the atrophied rat parotid gland due to duct-ligation and described that the striated ducts appeared to be qualitatively more prominent in the lobules than normally; their basal striations were still maintained in several instances. Intralobular and interlobular collecting ducts appeared dilated.

This finding agreed with our study as it was clear that duct dilatation occurred whenever the gland was atrophied or there was impairment in its function as what happened in our study.

We could understand from the previous study that dilatation of the ducts in our study occurred due to glandular damage and dysfunction caused by nutmeg administration.

In addition to vacuolisation and ductal dilatation, presence of congested blood vessels was a very obvious feature in nutmeg treated parotid glands.

[Scott, Liu, & Smith, 1999] Reported an increased vascularity in duct-ligated rat parotid glands.

Moreover, Moubarak [2012] detected numerous congested blood vessels engorged with red blood cells. The dilatation and congestion of the blood vessels were attributed to microcirculatory disturbances that developed due to amitriptyline administration that played an important role in glandular degeneration.

Immunohistochemical expression of proliferating cell nuclear antigen (PCNA)

Moubarak [2008] attributed that the dilatation and congestion of the blood vessels might be a part of inflammatory response to bring more blood to the areas of fibrosis or degeneration. This agreed with our study.

Presence of inflammatory cells in the C.T. stroma in experimental subgroups 3 and 4 was also detected in the present study.

Sections of mice liver treated with 500 mg/kg of nutmeg essential oil for 7 days showed focal area of degeneration and necrosis with infiltration of mononuclear cells and also section of mice liver treated with 1000 mg/kg showed more degenerative changes and necrosis of hepatocytes with focal mononuclear cells infiltration [Al-Jumaily *et al.*, 2012].

In our current study, immunohistochemical results revealed weak +ve immune reaction for PCNA in the control group, while the intensity of PCNA reactivity increased as the duration and dose increased in the experimental groups. These observations were confirmed with statistical analysis of area% of PCNA reaction.

Sugito *et al.*, [2009] stated that salivary gland epithelial cells normally divide very slowly. That is why only low levels of PCNA staining were evident in saline-treated mice. This totally agreed with our results for the control group.

In addition to that, Stramandinoli-Zanicotti *et al.*, [2013] stated that salivary glands have highly differentiated cells and a slow proliferation rate.

Moreover, Sumitomo *et al.*, [1996] reported that PCNA-positive nuclei were rarely observed in the normal glandular parenchyma.

Regarding the immunohistochemical results in the experimental groups of this study, the nuclei of the acinar cells revealed moderate +ve PCNA expression in subgroups 1 and 2, while in subgroups 3 and 4 both the nuclei of the acinar cells and the ducts revealed intense +ve PCNA expression. The cytoplasm of the acinar cells also showed weak +ve PCNA expression in subgroups 3 and 4.

Quantitatively, the expression of the PCNA protein varies over the course of the cell cycle, elevated levels appearing first during late G₁, becoming maximal during S phase, and declining again during G₂ and M phases, accompanied by a corresponding variation in the intensity of immunostaining

[Burford-Mason, Cummins, Brown, MacKay, & Dardick, 1993].

In interpreting PCNA immunohistochemistry it is important to note that PCNA expression increases during DNA synthesis that accompanies DNA excision repair. Positive PCNA staining may therefore reflect either cellular proliferation, active DNA repair, or both. [Burford-Mason, Cummins, Brown, MacKay, & Dardick, 1993]. We postulated from that point that positive PCNA staining observed in our experimental groups reflected the attempt of the cells to undergo repair to limit the damage caused by nutmeg administration.

Burford-Mason *et al.*, [1993] explained that acinar cells, as well as cells at all levels of the duct system, were capable of proliferation under a variety of physiological and experimental conditions. Acinar cells which proliferated rapidly and extensively under conditions of atrophy and during regeneration, might well be at particular risk of neoplastic transformation.

Dwivedi *et al.*, [2013] reported that current histogenetic classification of salivary gland tumors was based on the hypothesis that repair and replacement of terminally differentiated components of salivary gland such as duct epithelium and acinar cells were totally dependent on reserve or stem cells. However, the weight of evidence indicated that cell renewal and gland regeneration were functions of each of the various cell types in salivary gland, (i.e., acinar cells), as they formed the bulk of the gland parenchyma, presenting the greatest proportion of cycling cells in rat and human salivary glands.

We could get from the previous studies that the risk of neoplastic transformation in the nutmeg-treated parotid gland was present which was assured by the appearance of nuclear degenerative changes (e.g. abnormal mitosis, hyperchromatism,... *etc.*) reported in our study.

Furthermore, Gillespie *et al.*, [2008] reported that many of the PCNA-positive cells showed cytoplasmic localization; which simulates our results in subgroups 3 and 4. Cytoplasmic localization of PCNA raises the possibility of inappropriate intracellular trafficking. Consistent with this, some ducts showed immunostaining for PCNA in the lumen, suggesting secretion. This could account, in part, for PCNA being targeted as an autoantigen.

Moreover, Al-Refai *et al.*, [2014] stated that the complex relation between cell proliferation, differentiation, and apoptosis is a cardinal feature in main-

_____ Immunohistochemical expression of proliferating cell nuclear antigen (PCNA) tenance of the normal architecture and function of the submandibular gland. This also holds true in the parotid gland in the present study.

Eventually we believe that, proliferation of cells that occurred in the parotid gland in our present study was in an attempt to form new glandular tissue in order to compensate for the damage caused by the toxic effect of nutmeg.

Conclusion

From our findings we concluded that: Administration of nutmeg had damaging and teratogenic effects on the parotid glands especially when taken at high doses and for long durations.

References:

- Adjene, J. O. (2010). Histological effects of chronic consumption of nutmeg on the superior colliculus of adult Wistar rats. *International Journal of Biomedical and Health Sciences*, 6(2), 51-55.
- Adjene, J. O., & Nwose, E. U. (2010). Histological effects of long term consumption of nutmeg on the medial geniculate body of adult Wistar rats. *North American Journal of Medical Sciences*, 2(3), 134-137.
- Al-Jumaily, E. F., Al-Amiry, M. H., & Assad, J. I. (2012). Hepatotoxic activity of essential oil from nutmeg (*Myristica fragrans*) against tetrachloride-induced hepatic damage in mice. *IOSR Journal of Pharmacy and Biological Sciences*, 2(6), 1-8.
- Al-Refai, A. S., Khaleel, A. K., & Ali, S. (2014). The effect of green tea extract on submandibular salivary gland of methotrexate treated albino rats: Immunohistochemical study. *J. CytolHistol*, 5(2), 1-6.
- Burford-Mason, A. P., Cummins, M. M., Brown, D. H., MacKay, A. J., & Dardick, I. (1993). Immunohistochemical analysis of the proliferative capacity of duct and acinar cells during ligation-induced atrophy and subsequent regeneration of rat parotid gland. *J Oral Pathol Med*, 22, 440-446.
- Cardoso, W., Denardum, O., Rapoport, A., Araujo, V., & Carvalho, M. (2000). Proliferating cell nuclear antigen expression in mucoepidermoid carcinoma of salivary glands. *Sao Paulo Medical Journal*, 118(3), 69-74.
- Dwivedi, N., Agarwal, A., Raj, V., & Chandra, S. (2013). Histogenesis of salivary gland neoplasms. *Indian Journal of Cancer*, 50(4), 361-366.
- Foley, J., Ton, T., Maronpot, R., Butterworth, B., & Goldsworthy, T. L. (1993). Comparison of Proliferating Cell Nuclear Antigen to Tritiated Thymidine as a marker of proliferating hepatocytes in rats. *Environmental Health Perspec-*

- tives, 101(5), 199-206.
- Gillespie, K., Kodani, I., Dickinson, D. P., Ogbureke, K. U., Camba, A. M., Wu, M., *et al.*, (2008). Effects of oral consumption of the green tea polyphenol EGCG in a murine model for human Sjogren's syndrome, an autoimmune disease. *Life Sci.*, 83(17-18), 581-588.
 - Henics, T., & Wheatley, D. N. (1999). Cytoplasmic vacuolation, adaptation and cell death: A view on new perspectives and features. *Biology of the Cell*, 91, 485-498.
 - Kisby, D. (2003). Nutmeg. *Utox Update*, 5(4), 1, 2.
 - Leela, N. K. (2008). Chemistry of spices. (B. C. Villupanoor A.Parthasarathy, Ed.) CAB International.
 - Leslie, B. A., & Putney, J. W. (1983). Ionic mechanisms in secretagogue- induced morphological changes in rat parotid gland. *The Journal of Cell Biology*, 97, 1119-1130.
 - Madsen, P., & Celis, J. E. (1985). S-phase patterns of cyclin (PCNA) antigen staining resemble topographical patterns of DNA synthesis. *Federation of European Biochemical Societies*, 193(1), 5-11.
 - Malviya, N., Jain, S., Gupta, V. B., & Vyas, S. (2011). Recent studies on aphrodisiac herbs for the management of male sexual dysfunction- A Review. *ActaPoloniaePharmaceutica- Drug Research*, 68(1), 3-8.
 - Mattioli, T. M., da Silva, S., Gregio, A. M., Machado, M. A., de Lima, A. A., & Azevedo-Alanis, L. R. (2011). The effects of antidepressants and pilocarpine on rat parotid glands: an immunohistochemical study. *Clinics*, 66(9), 1605-1610.
 - Moubarak, R. (2008). The effect of rat parotid salivary glands (histopathological and immunohistochemical study). *Cairo Dental Journal*, 24(I), 19-28.
 - Moubarak, R. (2012). Cytotoxic and apoptotic effects of chronic amitriptyline administration on rat parotid salivary glands. *Journal of American Science*, 8(1), 360-365.
 - Olaleye, M., Akinmoladun, A. C., & Akindahunsi, A. (2006). Antioxidant properties of *Myristicafragrans* (Houtt) and its effect on selected organs of albino rats. *African Journal of Biotechnology*, 5(13), 1274-1278.
 - Paunesku, T., Mittal, S., Protic, M., Oryhon, J., Korolev, S. V., Joachimiak, A., *et al.*, (2001). Proliferating cell nuclear antigen (PCNA): ringmaster of the genome. *Int. J. Radiat. Biol.*, 77(10), 1007-1021.
 - Rivero, E. R., Caliar, M. V., Tarquinio, S. B., Loyola, A. M., & de Aguiar, M. C. (2004). Proliferative activity in oral salivary gland tumors: the role of PCNA and AgNOR assessed by a double staining technique. *Journal of Oral*

Immunohistochemical expression of proliferating cell nuclear antigen (PCNA)

Science, 46(2), 87-92.

- Scott, J., Liu, P., & Smith, P. M. (1999). Morphological and functional characteristics of acinar atrophy and recovery in the duct-ligated parotid gland of the rat. *J Dent Res*, 78(11), 1711-1719.
- Stramandinoli- Zanicotti, R. T., Sassi, L. M., Schussel, J. L., Torres, M. F., Funchal, M., Smaniotto, G. H., *et al.*,. (2013). Effect of fractionated radiotherapy on the parotid gland: an experimental study in Brazilian minipigs. *Int Arch Otorhinolaryngol*, 17(2), 163-167.
- Strzalka, W., & Ziemienowicz, A. (2011). Proliferating cell nuclear antigen (PCNA): a key factor in DNA replication and cell cycle regulation. *Annals of Botany*, 107, 1127-1140.
- Sugito, T., Mineshiba, F., Zheng, C., Cotrim, A., Goldsmith, C., & Baum, B. (2009). Transient TWEAK overexpression leads to a general salivary epithelial cell proliferation. *Oral Dis.*, 15(1), 76-81.
- Sumitomo, S., Hashimura, K., & Mori, M. (1996). Growth pattern of experimental squamous cell carcinoma in rat submandibular glands: an immunohistochemical evaluation. *Eur J Cancer B Oral Oncol.*, 32B(2), 97-105.
- Tandon, P. N., Mahajan, R. C., Anand, N., Basu, S. K., Ganguly, N. K., Kamboj, V. P., *et al.*,. (2000). Guidelines for care and use of animals in scientific research. New Delhi: Indian National Science Academy.